

**PATIENT**  
Sophie Amin

**PRESENTING CLINICAL SIGNS**  
History: PLE, GB mucocele surgery. H/O MR  
Current medications: Pimobendan, visbiome, pred, cosequin

**SPECIES**  
Canine

**ELECTROCARDIOGRAPHIC FINDINGS** \*Note: Single lead ECGs are evaluated as a rhythm strip.  
Morphology/MEA cannot be definitively commented on.

**BREED**  
Poodle Mix

A single lead ECG is available from an AliveCor monitor; 50mm/s, 20mm/mV. The average heart rate is 140bpm (range 200-166bpm). The rhythm is sinus in origin, with a p for every QRS complex and vice versa. No ectopic beats, pauses or other dysrhythmias observed.  
ECG diagnosis: Normal sinus rhythm with respiratory variation.

**SEX**  
FS

**CARDIAC CHART**

**AGE**  
2013

**WEIGHT**  
15.2

**INTERPRETED BY**  
Maggie Machen Lamy,  
DVM, DACVIM  
(Cardiology)

FELINE CARDIAC PARAMETERS	BODY WEIGHT (kg)	HR (BPM)	IVSd (cm) (Moise, Pipers)	LVIDd (cm) (Moise, Pipers)	LVWd (cm) (Moise, Pipers)	FS (%)	EF (%)
NORMAL PARAMETER	-----	150-240	0.35-0.55	<2 (mean 1.5)	3.5-0.55	35-67	80-100
<b>PATIENT</b>							
FELINE CARDIAC PARAMETERS	LA/AO (Boon)	LA/AO HEART BASE (Swe) (Abbott)	LA 2D short axis Base view (cm) (Abbott)		LVOT VEL (m/s)	RVOT VEL (m/s)	E max (m/s)
NORMAL	<1.5	<1.3	<1.2		<1.6	<1.3	<0.9
<b>PATIENT</b>							
<i>*Note: All measurements based upon multi-modal images and methods. An average value is reported.</i> Adapted from June Boon, Veterinary Echocardiography, 1998 Abbott J & MacLean H JVIM 2006;20: 111-119, Moise et al. Am J Vet Res 47:1476, 1986. Pipers et al. Am J Vet Res 40:882, 1979.							

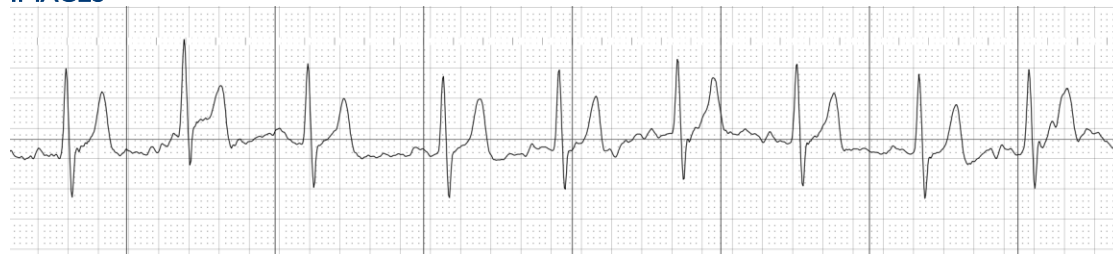**IMAGING PERFORMED BY**  
Rebekah Jakum, CVT  
ARDMS/RVT

**INTERPRETATION OF THE FINDINGS & FURTHER RECOMMENDATIONS**

The submitted ECG is normal, with no evidence of dysrhythmias. If these findings do not reflect what was auscultated on exam (ie premature beats), a longer recording or potentially a holter monitor may be necessary.

**HOSPITAL NAME**  
New Britain VC

**IMAGES**



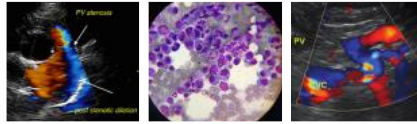
**REFERRING VET**  
Dr. Bandekar

**INVOICE**  
25486

The information and recommendations provided are based on the images presented by the referring veterinarian. No evaluation can be communicated regarding pathology that was not visible in the image/video clips provided.

**DATE**  
7/21/22

Thank you for this referral. If the clinical or image interpretation does not parallel your findings or if I



**PATIENT**

Sophie Amin

can be of any further assistance, please contact me.

**Maggie Machen Lamy, DVM**  
Diplomate of the American College of Veterinary Internal Medicine (Cardiology)  
info@sonopath.com

**SPECIES**

Canine

**BREED**

Poodle Mix

**SEX**

FS

**AGE**

2013

**WEIGHT**

15.2

**INTERPRETED BY**

Maggie Machen Lamy,  
DVM, DACVIM  
(Cardiology)

**IMAGING  
PERFORMED BY**

Rebekah Jakum, CVT  
ARDMS/RVT

**HOSPITAL NAME**

New Britain VC

**REFERRING VET**

Dr. Bandekar

**INVOICE**

25486

**DATE**

7/21/22